TCTAP 2019
Seoul, Korea, Apr. 27-30, 2019

Tricuspid Valve Implantation: Current Data and Future Perspectives

Kolja Sievert,

Ilona Hofmann, Sameer Gafoor, Stefan Bertog, Predrag Matić, Markus Reinartz, Bojan Jovanovic, Iris Grunwald, Nalan Schnelle, Horst Sievert

CardioVascular Center Frankfurt - CVC,

Frankfurt, Germany

No Disclosures

Catheter treatment of tricuspid valve insufficiency

- More technical challenges compared to other valve interventions:
  - Proximity of AV node and RCA
  - Leaflets and chordae are thinner than in mitral
  - Thin RV wall
  - Many patients have pacemaker leads
- Patient selection is difficult
  - difficult assessment of symptoms, variability of clinical status …
  - when is it to late and when too early?
- Imaging is difficult
- All repair techniques are in an early stage
- Tricuspid valve implantation may be an alternative

Transcatheter Tricuspid Valve Implantation

- Valve in surgical valve
- Ectopic valve implantation
  - Caval valve implants
  - CaValve
- CavalveTricuspid valve in native valve implantation
  - NaviGate
  - Trisol
  - LuX-Valve

Tricuspid Valve in Surgical Valve

J.S., 32 y/o, m

S.P. Tricuspid valve implantation at the age of 14 due to Epstein syndrome with tricuspid stenosis

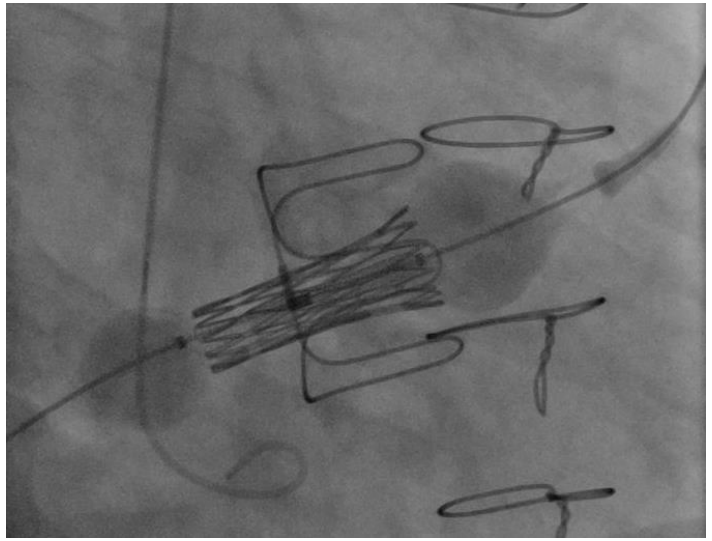

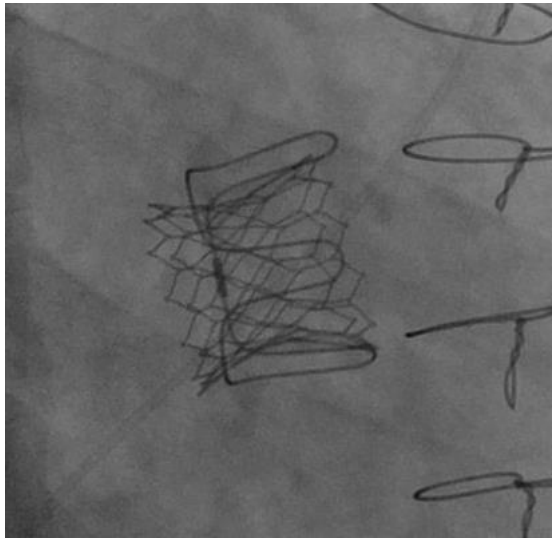

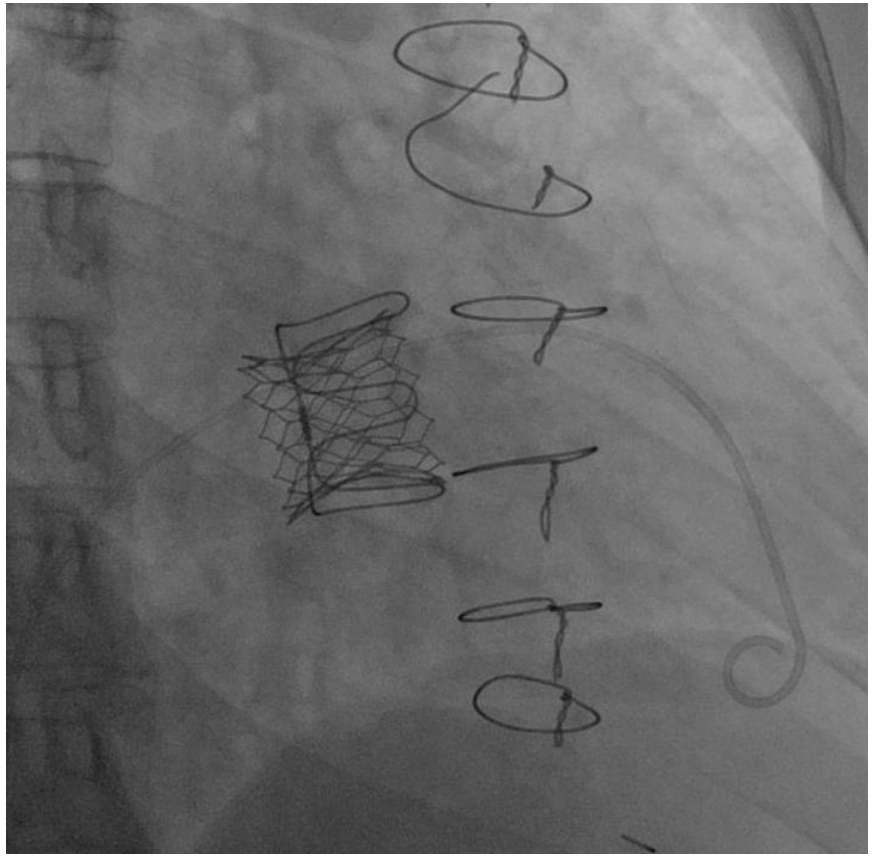

Degenerated surgical valve: 31 mm-Carpentier-Edwards

Transcatheter valve: 29 mm Sapien XT

Transcatheter Tricuspid Valve Implantation

- Valve in surgical valve
- Ectopic valve implantation
  - Caval valve implants
  - CaValve
- CavalveTricuspid valve in native valve implantation
  - NaviGate
  - Trisol
  - LuX-Valve

Transcatheter C A V I

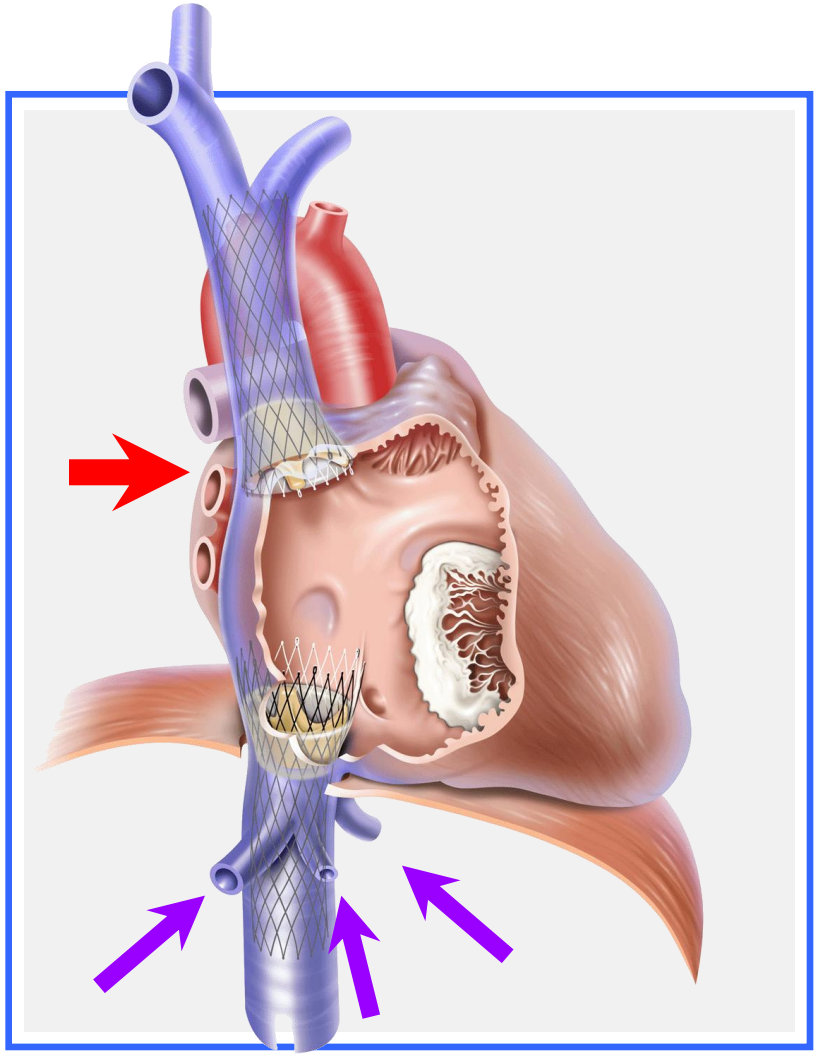

- Implantation of self-expandable valve in SVC
- Implantation of self-expandable valve in IVC at cavo-atrial junction above hepatic vein inflow

Alexander Lauten, Hans R. Figulla

Results

- FIM CAVI 08/2010 - Inclusion 08/2010 – 02/2017, 7 centers (6 in Germany, 1 in Canada)
- 100% compassionate cases

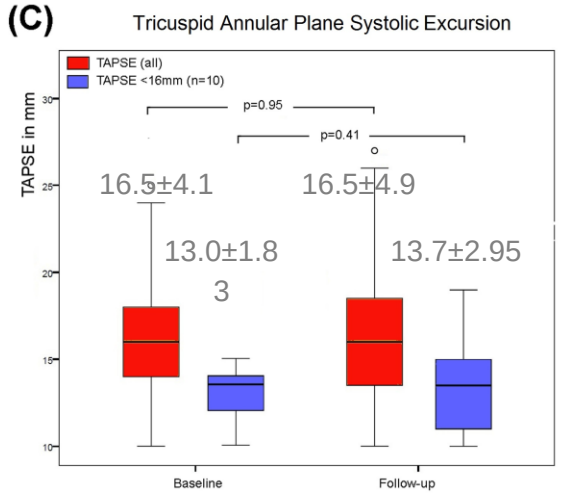

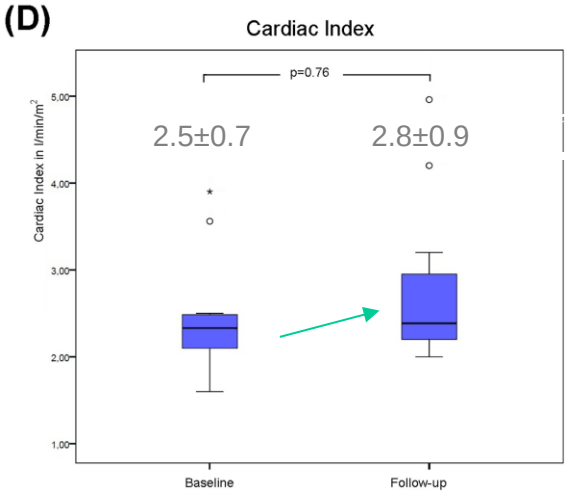

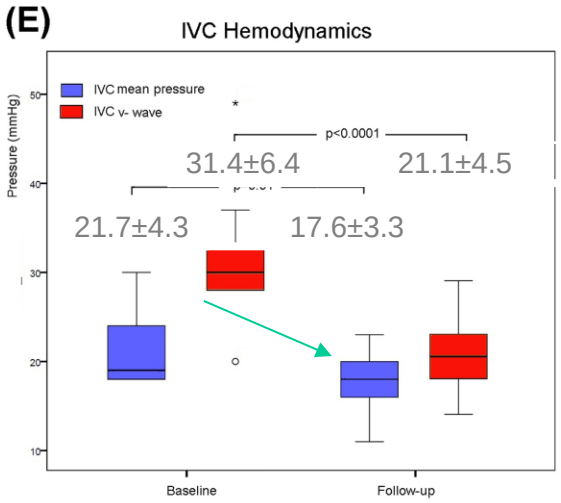

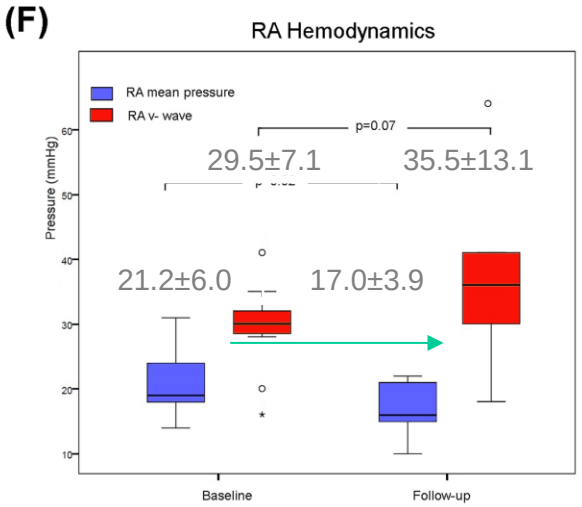

NYHA-Class

Baseline vs. Discharge

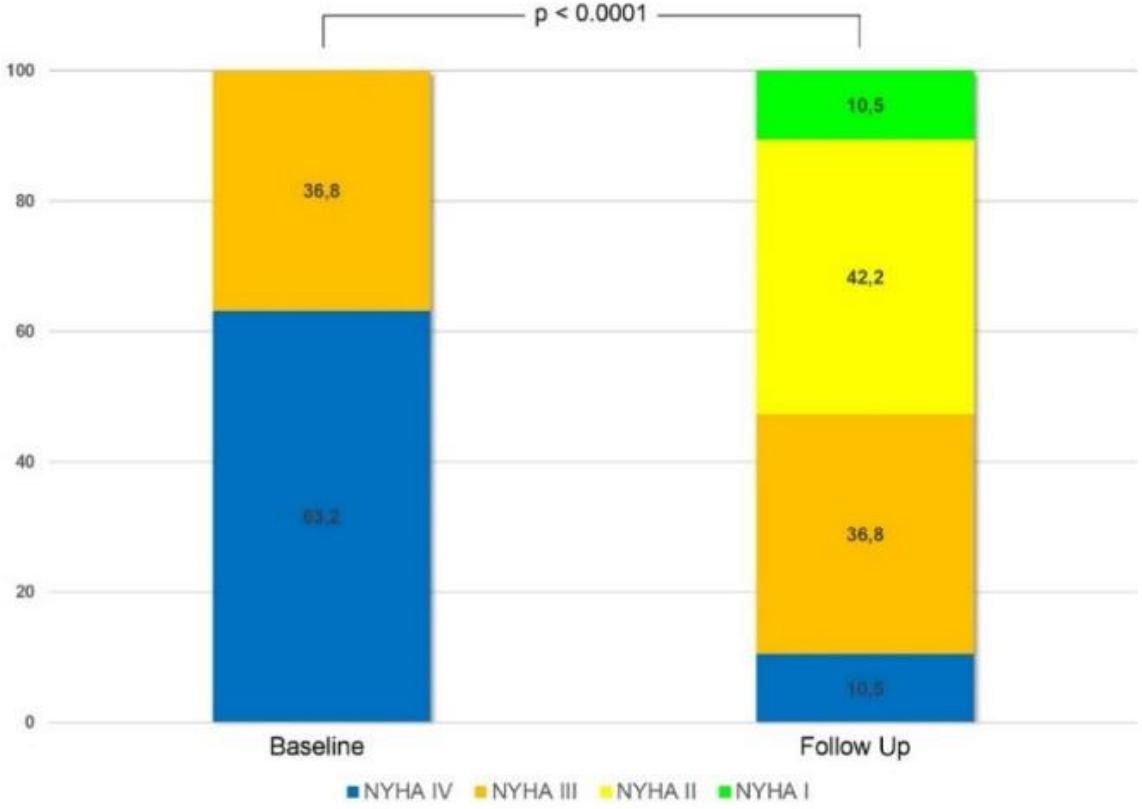

Lauten A Circ Cardiovasc Interv 2018;

New concept: Cavalve

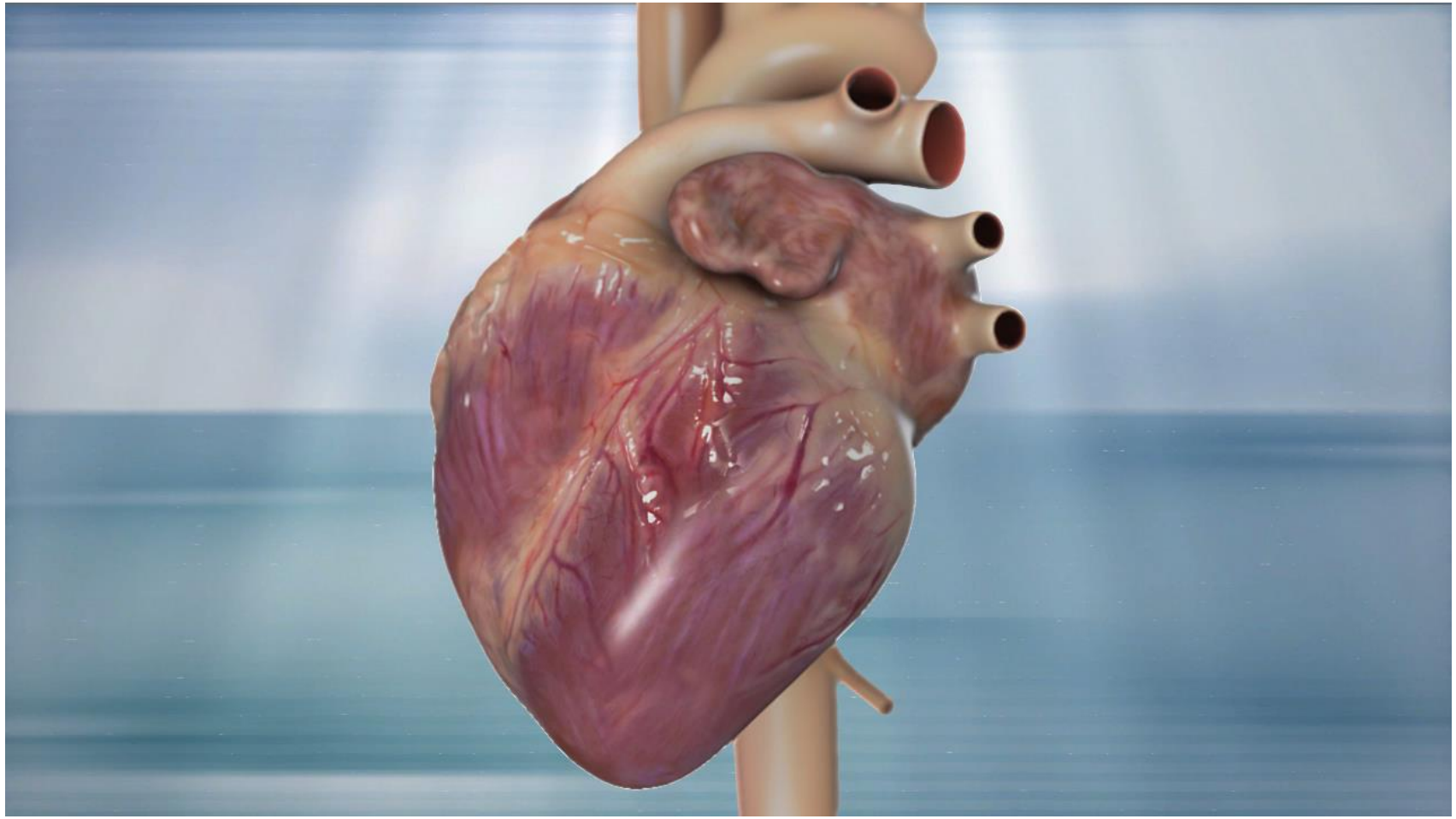

A stent graft structure that regulates inflow to RA through the stent graft wall

Anchoring is done in the tubular SVC and IVC

The stent graft can bare multiple valves

The native valve is left untouched

Pre-clinical

Transcatheter Tricuspid Valve Implantation

- Valve in surgical valve
- Ectopic valve implantation
  - Caval valve implants
  - CaValve
- Tricuspid valve in native valve implantation
  - NaviGate
  - Trisol
  - LuX-Valve

Valve in Native Valve: NaviGate Tricuspid Valve



- Made of a nitinol tapered stent, height 21 mm
- Annular winglets and leaflet anchors
- Valve sizes 36, 40, 44, 48, 52 mm
- 35 F sheath with OD 42 F
- Trans-jugular or right-atrial (mini-thoracotomy)
- Delivery system has two degrees of tip motion and allows a very controlled valve release

Transjugular access

- Internal jugular vein > 14mm
- > 7cm space between the sheath and the tricuspid valve

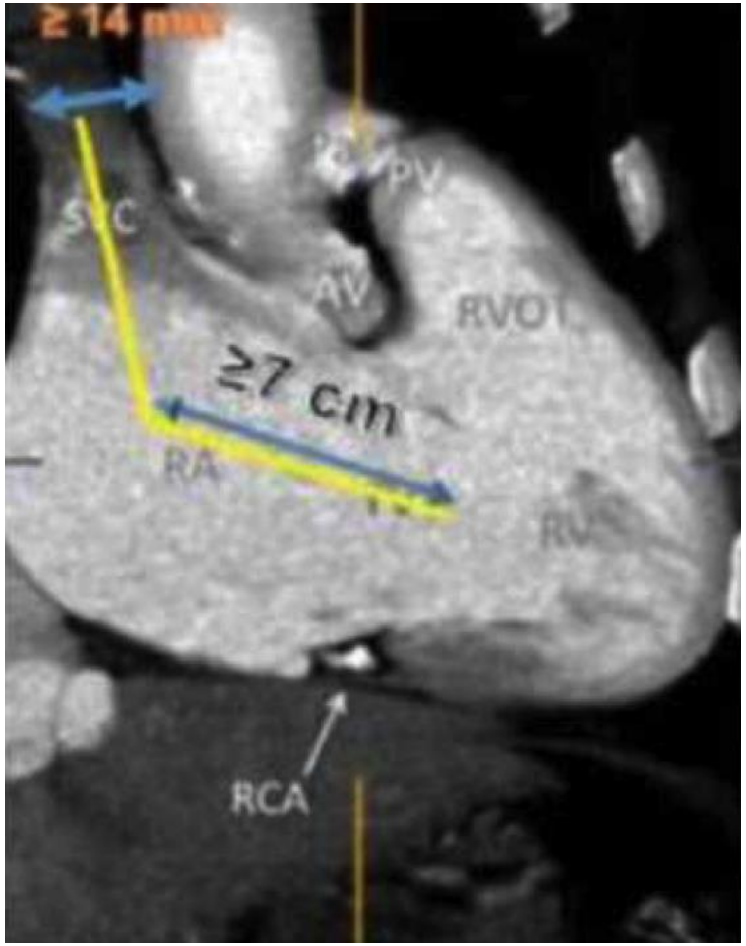

Preferred access: Transatrial

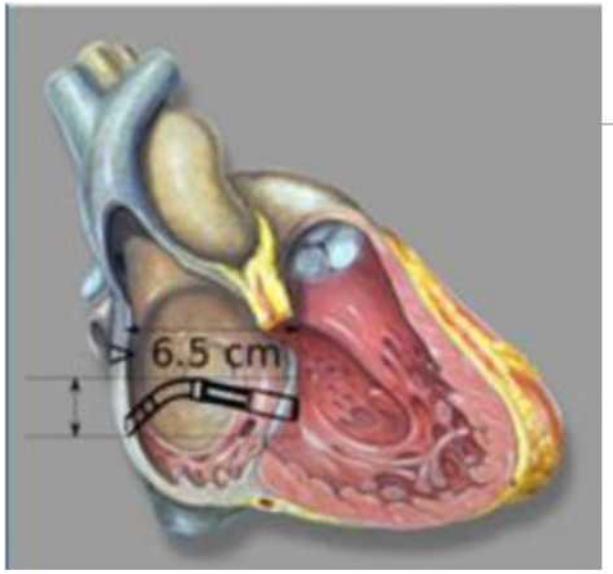

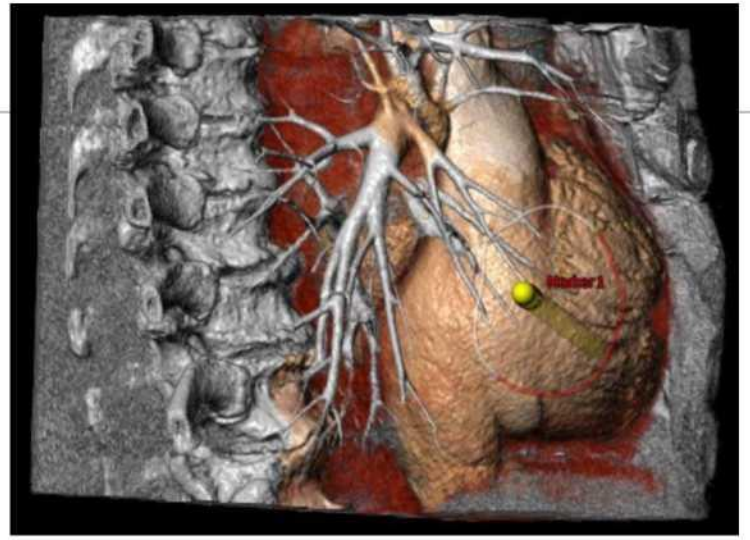

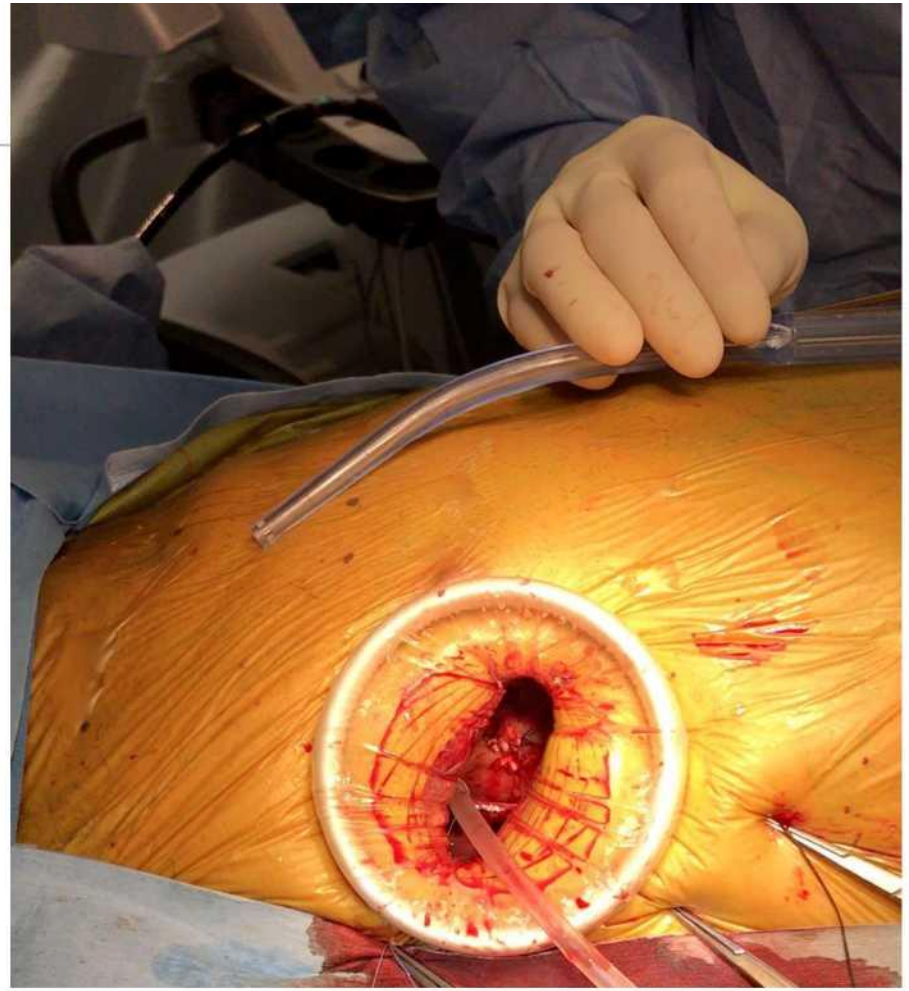

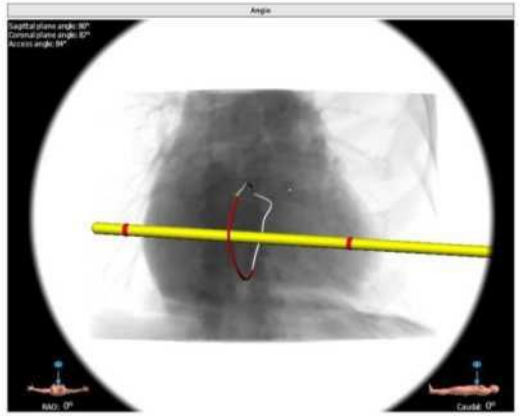

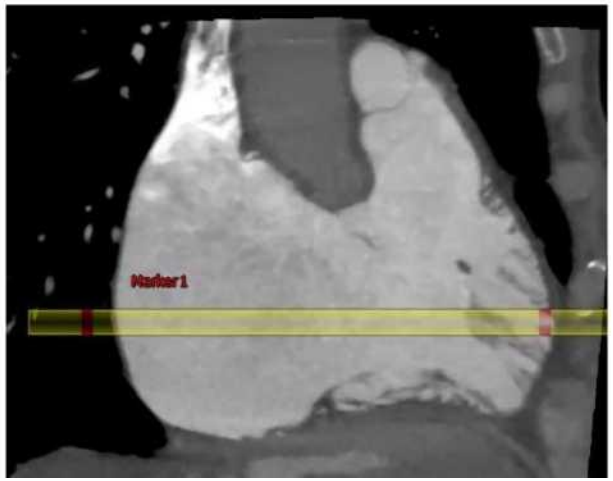

Navigate tricuspid valve implantation

1st patient in Frankfurt

- 80 y/o male patient
- S.P. surgical mitral valve replacement at the age of 61
- EF 45 %
- Severe tricuspid insufficiency
  - Recurrent hospital admissions due to right heart failure with severe pleural effusion, edema and ascites

- Atrial fibrillation
- Hypertension
- AAA

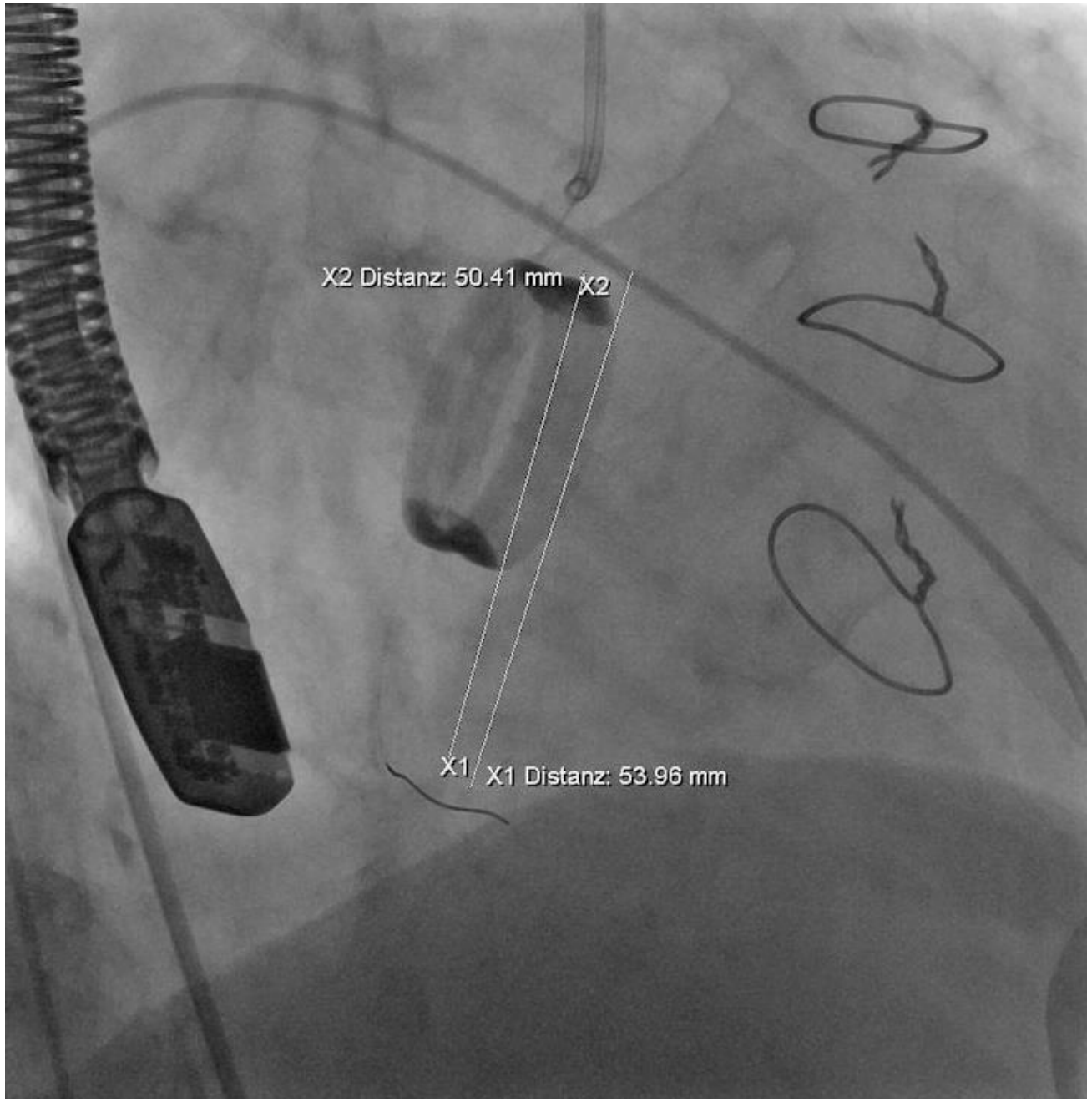

- Patient has also a mechanical valve in mitral position
- RV angiogram shows a very severe tricuspid regurgitation

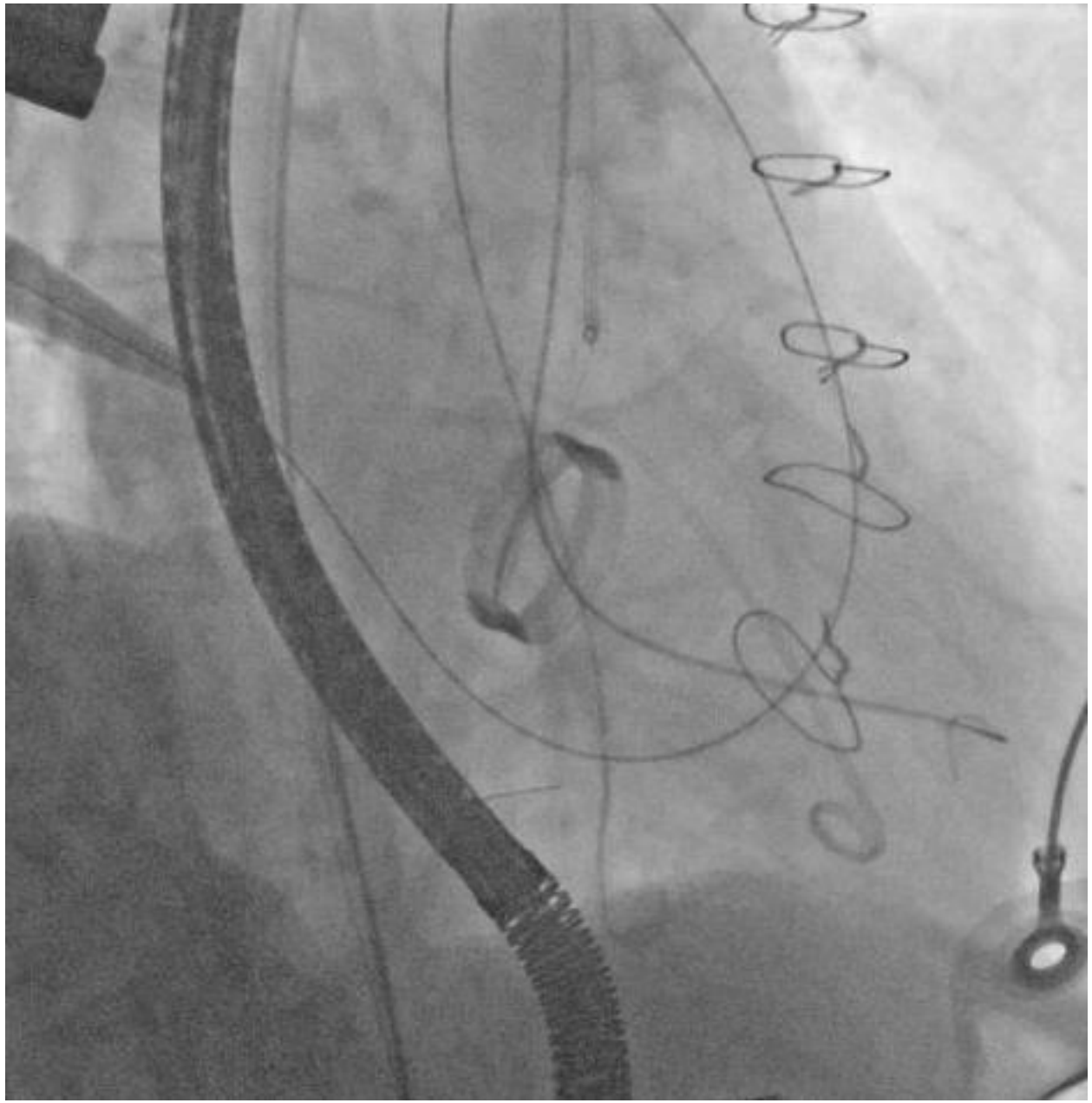

- Righ atrial access obtained via lateral mini-thoracotomy
- Stiff wire RA-RV-PA

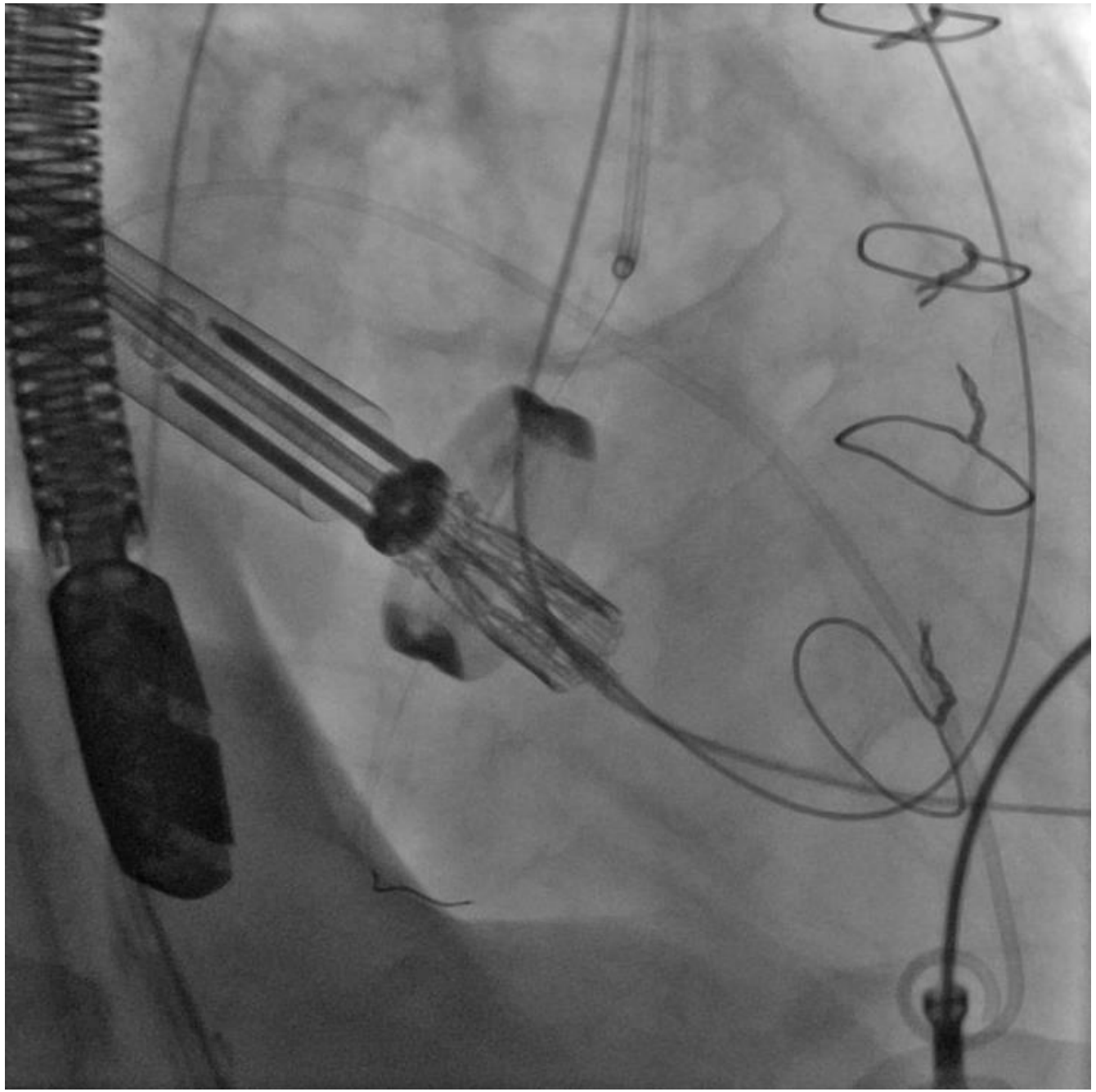

- Coronary wire in the RCA for fluoro guidance
- Navigate valve just prior to deployment

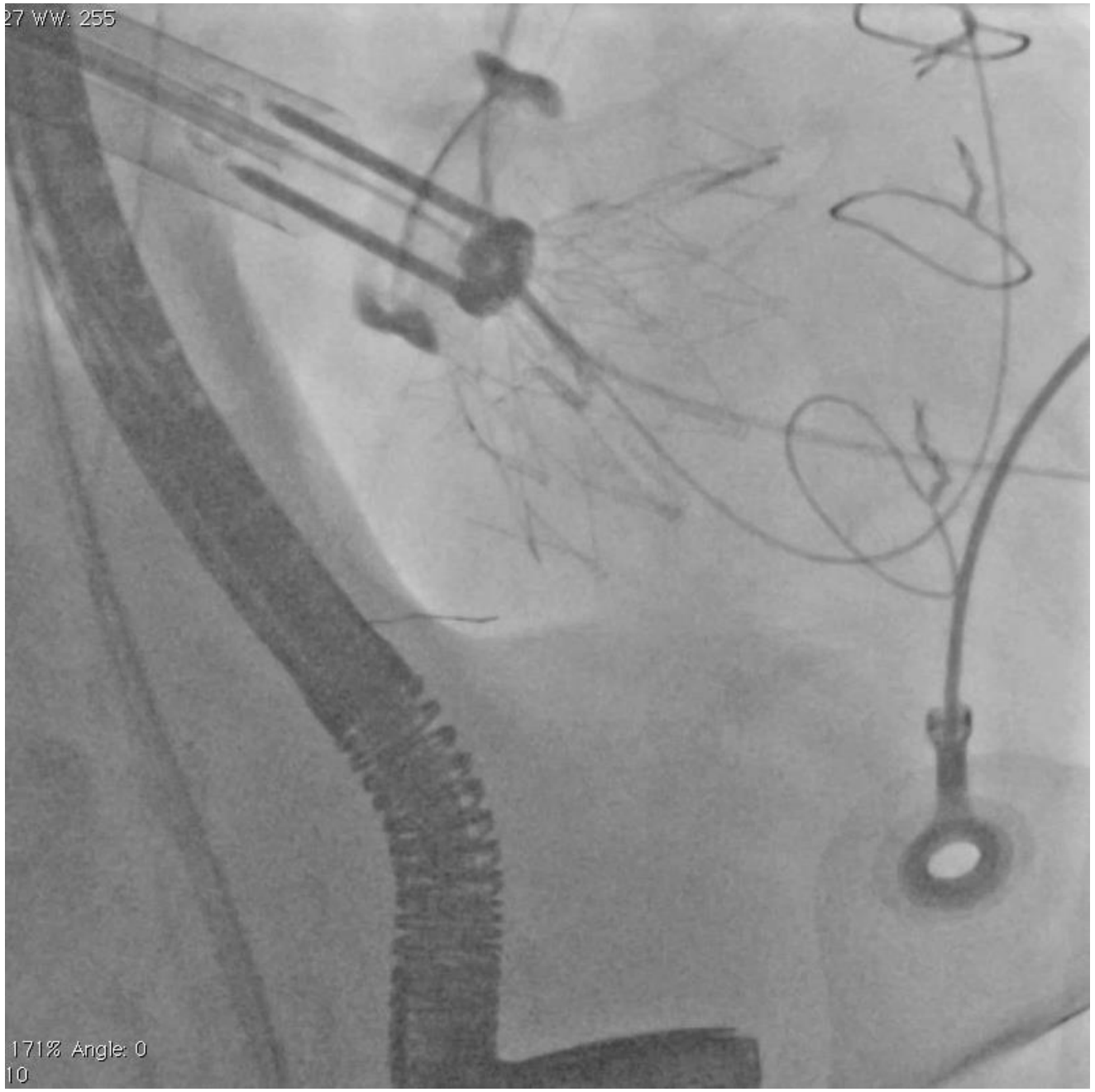

- During deployment, ventricular tines are exposed

CVC Frankfurt

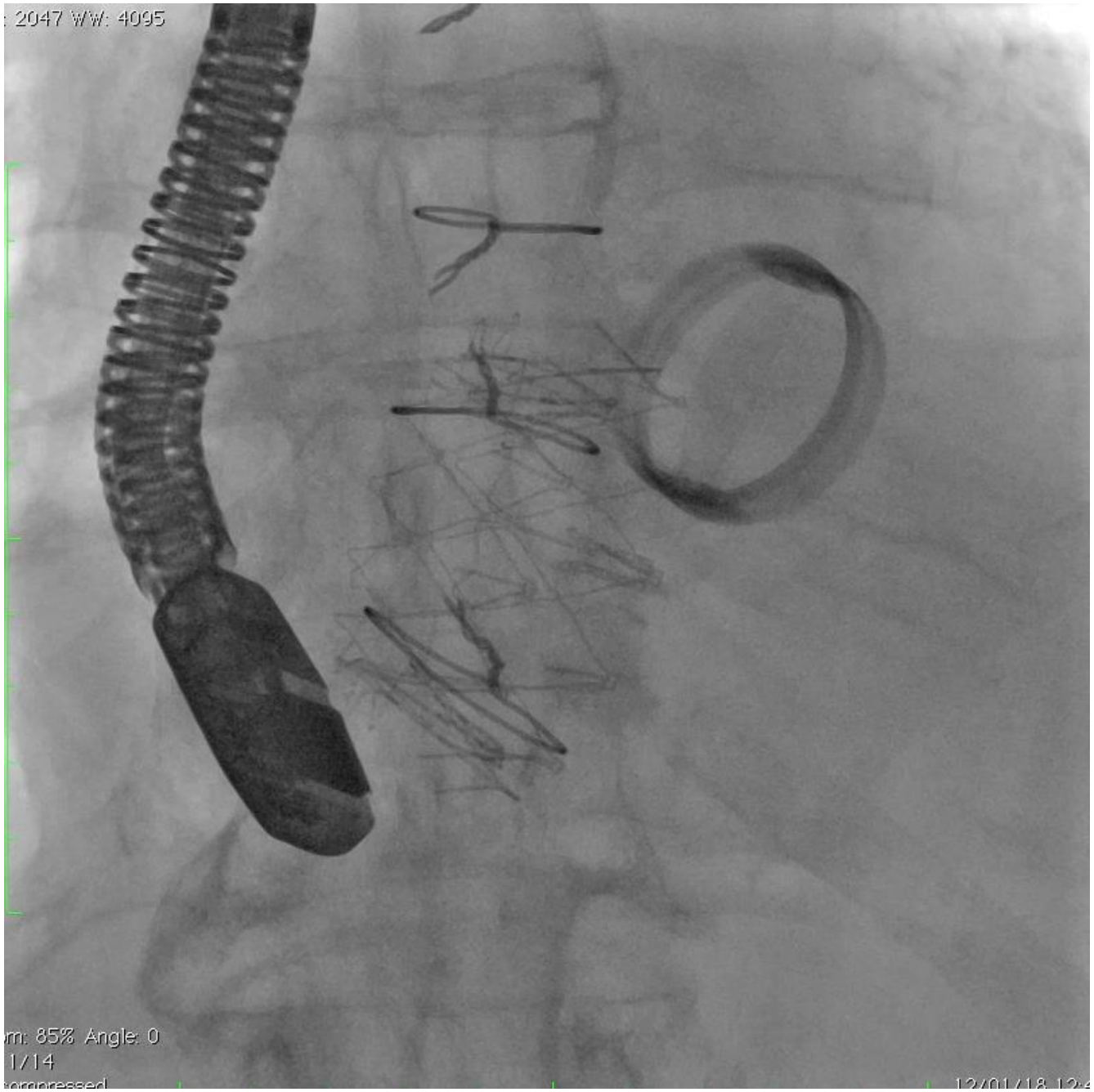

- After deployment

CVC Frankfurt

Navigate tricuspid valve implantation
1st patient in Frankfurt

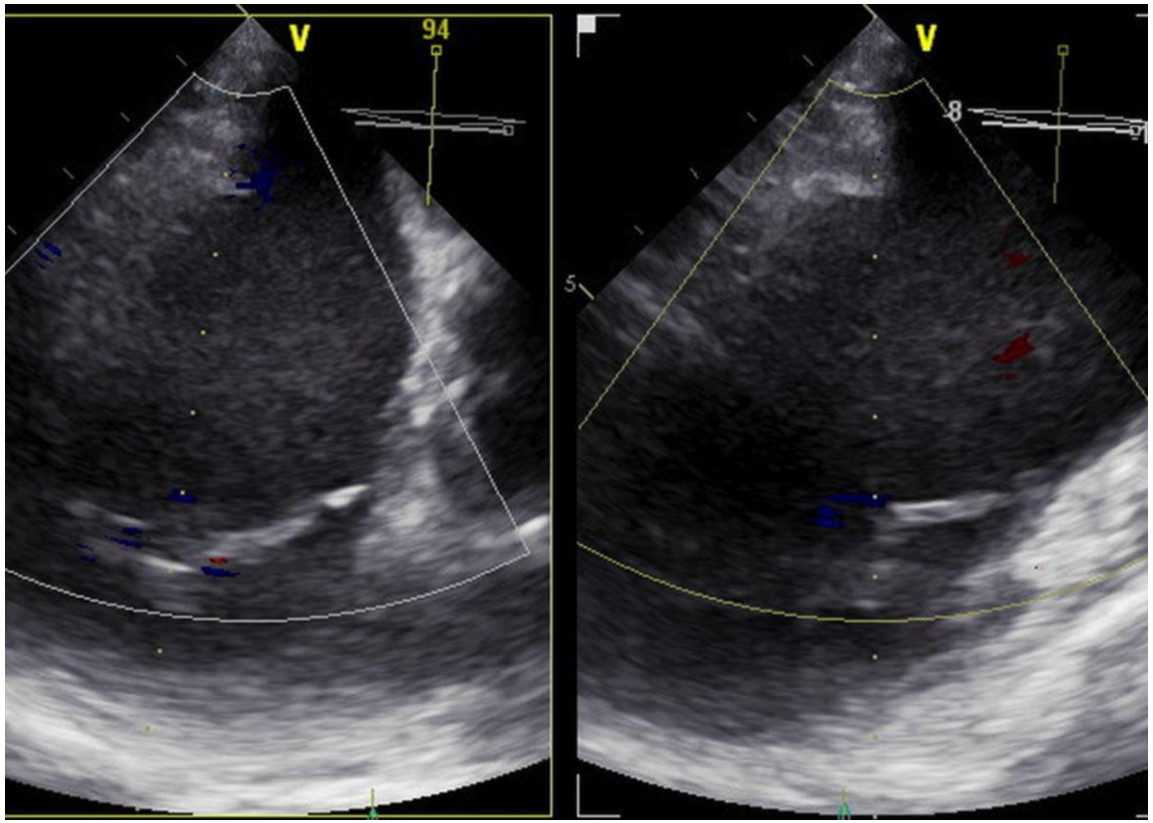

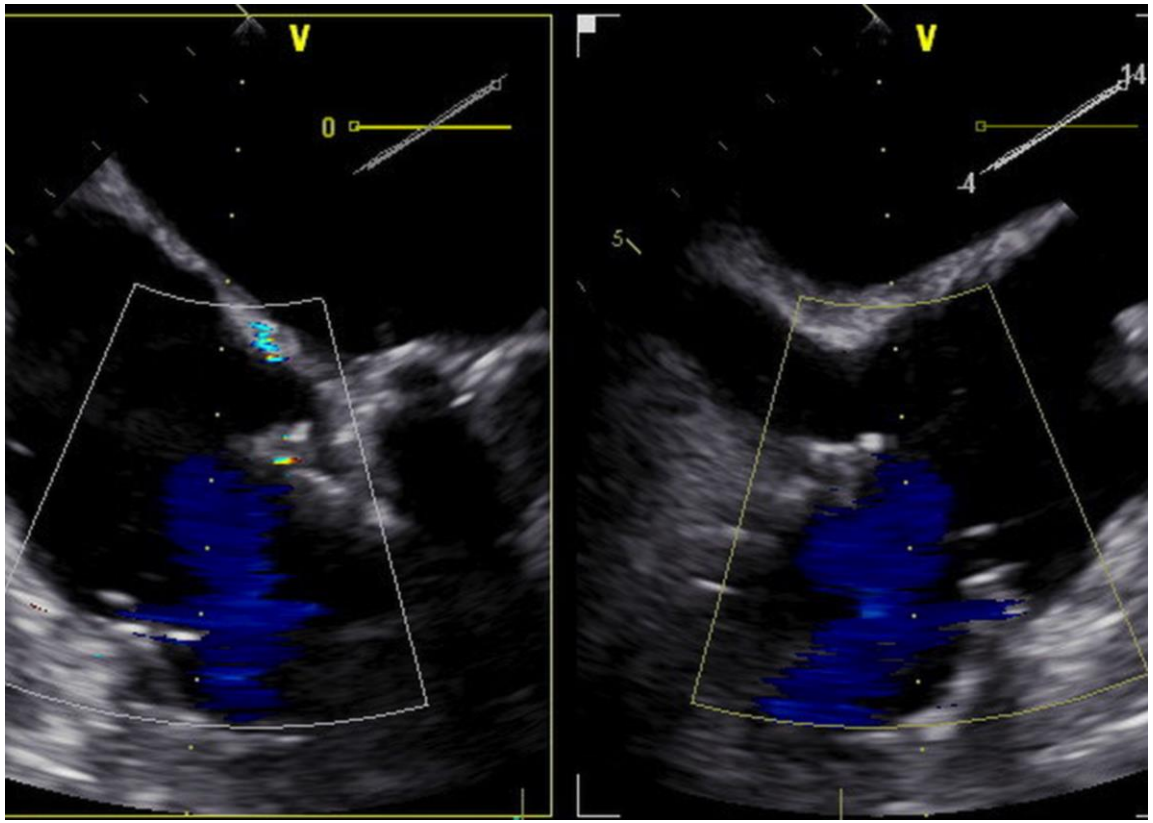

before

after

CVC Frankfurt

Patients (All Centers)

Site/City	Country	TA	TJ	# of Patients
Laval, Quebec	Canada	3	0	3
St. Michaels, Toronto	Canada	5	0	5
San Borja, Santiago	Chile	1	0	1
CVC, Frankfurt	Germany	2*	2*	4
Padua, Padua	Italy	0	3	3
San Raffaele, Milan	Italy	0	1	1
John Paul II, Krakow	Poland	2	1	3
Puerta De Hierro, Madrid	Spain	1	0	1
USZ, Zurich	Switzerland	4	0	4
CCF, Cleveland	USA	3	1	4
CUMC, New York	USA	5	0	5
Northwestern, Chicago	USA	1	0	1
SFH, Roslyn , NY	USA	2	0	2
Total		**29**	**8**	**37**

Patient baseline characteristics

	% or Mean ± SD
Age (years)	73.5 ± 12.5 yrs
Female	53%
Baseline NYHA class III or IV	63%
Atrial fibrillation	84%
Diabetes	59%
CAD	63%
Prior CABG	41%
Prior valve interventions	66%
Valve surgery (2x mitral, 1x aortic, 1x aortic & mitral)	44%
Transcatheter valve repair/replacement	22%
Renal dysfunction	59%
RV Dysfunction	84%
Prior stroke or TIA	9%
Systemic hypertension	41%
Prior intracardiac device (PPM or ICD)	19%
Heart transplant	9%

Very sick patient population!

Acute results

	TA	TJ	Total
Attempts	29	8	37
Successful implant (pts)	24	3	27
Implantation not successful*	1	4	5
Conversion to surgery	4	1	5

***2 Intent-to-treat patients by TJ-access became TA – access patients at a later time. Hence total number of patients is 32**

Implanted valves

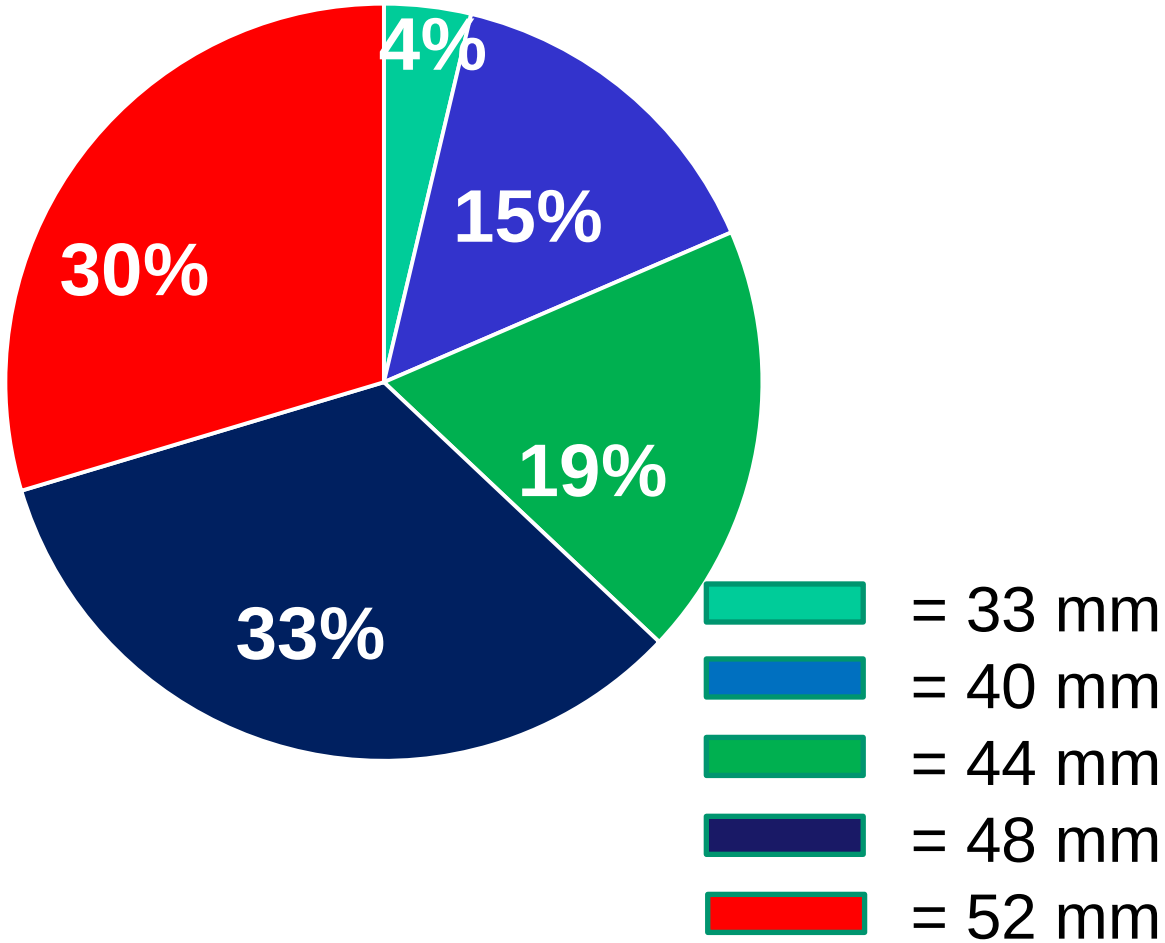

NaviGate Transcatheter Tricuspid Valve Implants

Tricuspid Regurgitation

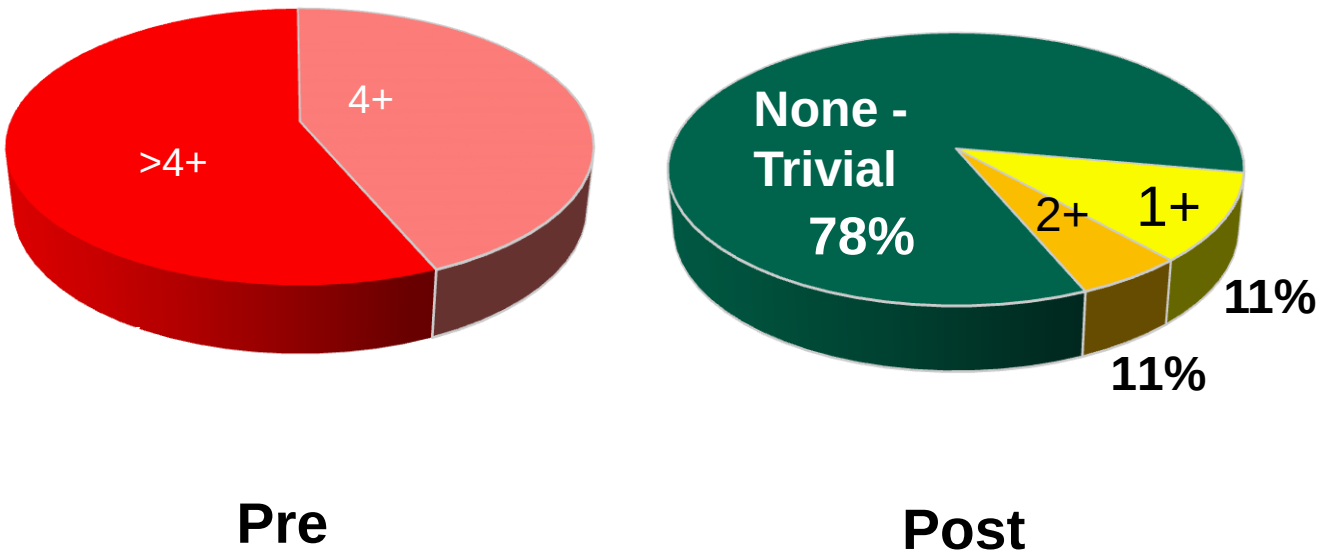

NYHA Class

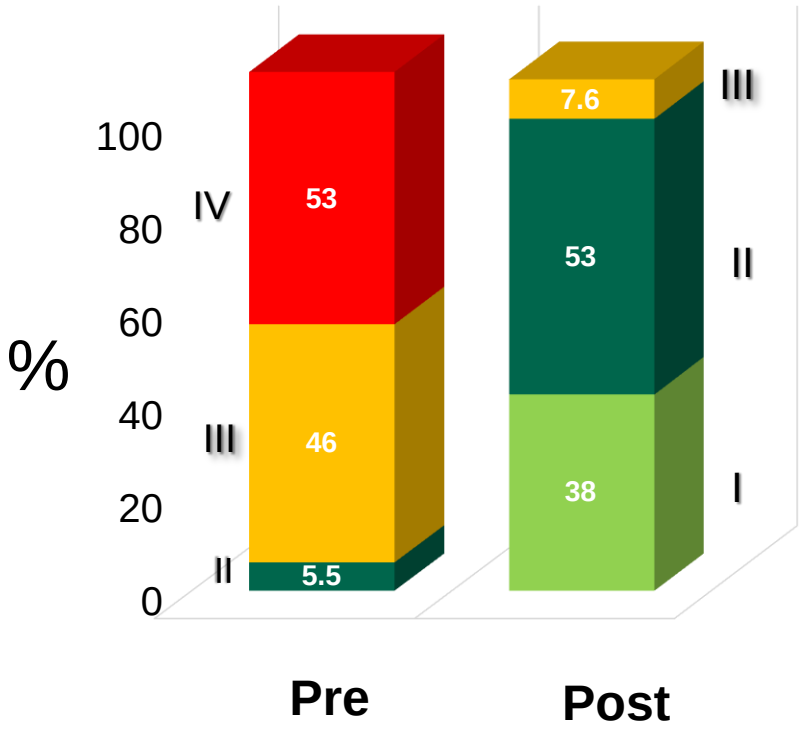

Trisol

- Unique valve design
- Transjugular approach
- 30F delivery system
- The valve anchors on the leaflets
- Can be repositioned and retrieved
- Animal test ongoing

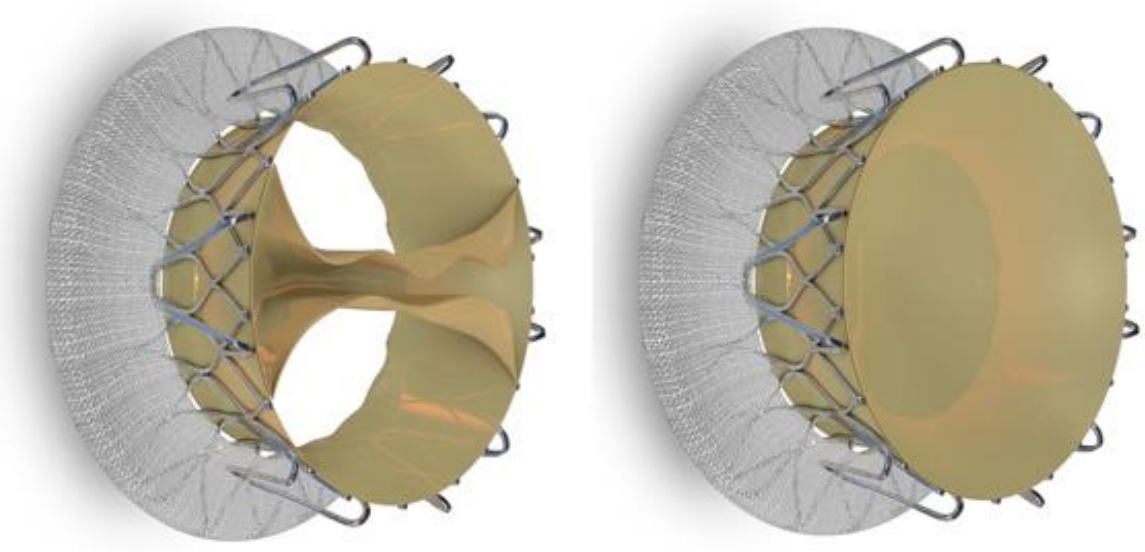

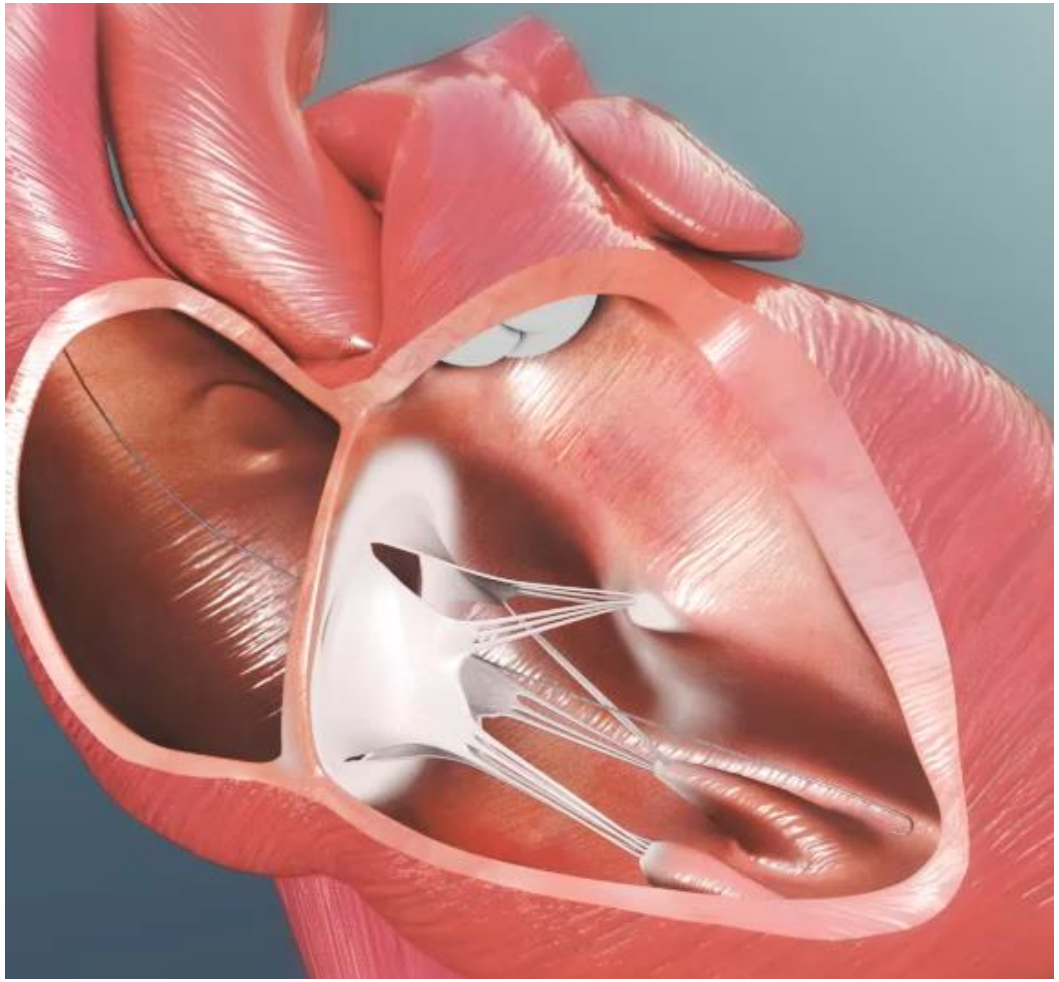

LuX-Valve

- Soft Valve Disc
  - Attached on the leaflets and TV annulus
  - Sizes: 50, 60, 70mm
- Two graspers for anterior leaflet
- One interventricular anchor (IVA)
- Inner diameter: 26 or 28mm
- Valve size based on effective orifice area – not size of annulus
- Fixation not dependent on radial force
  - depends on anterior cusp and interventricular septum
- Avoids paravalvular leak by the attachment between disc and leaflets

China Valve/CSI 2019, Zhiyun Xu,

LuX-Valve

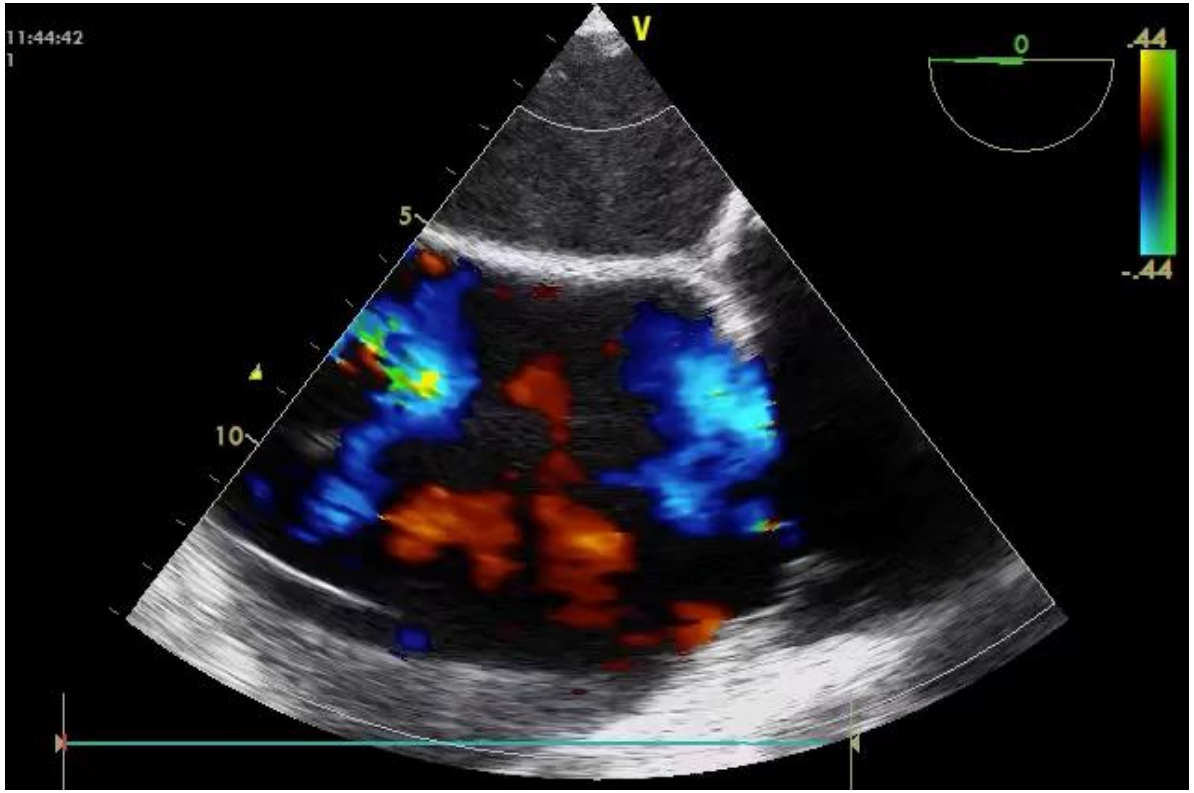

Preoperative TEE

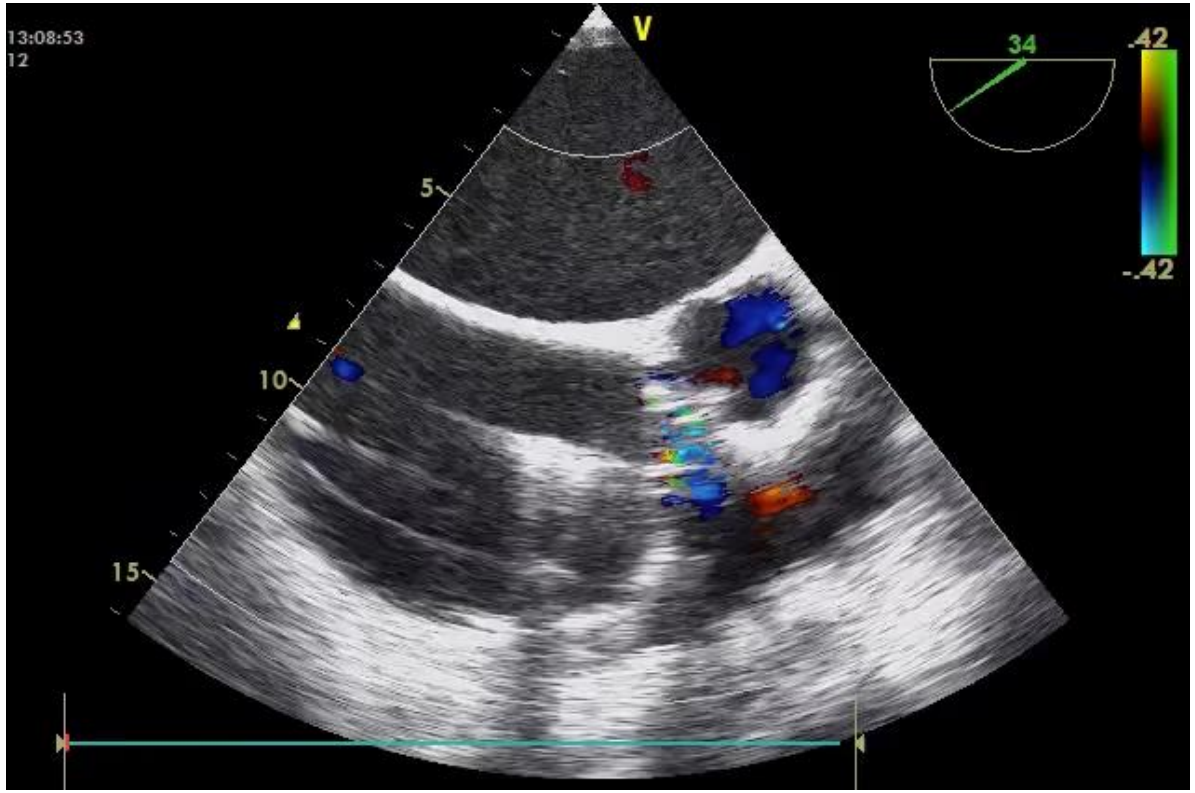

Postoperative TEE

China Valve, Zhiyun Xu, Fanglin Lu

LuX-Valve - Early clinical results

- n=15
- Successful implantation in all patients
- 30-day mortality 6.7%
  - 1 Death due to myocardial infarction

	Before Operation	Post operation
LVEF	54.7±6.5	55.7±5.1
Prosthetic valve migration		
Regurgitation (ml)	47.5±10.3	0
Perivalvular leakage (ml)		1.9±1.9
Transtricuspid gradient (mmHg)	1.1±0.2	1.0±0.3
Tricuspid annulus diameter (mm)	45.5±4.3	40.5±4.3
RA Volume (ml)	194.0±108.6	160.8±57.3
RV volume (ml)	71.9±11.4	65.4±20.3

China Valve/CSI 2019, Zhiyun Xu, Fanglin Lu

Tricuspid valve implantation has taken off!